



Hydrallantois in beef cattle: Two case reports

García, J.P.^{1,2*} ; Riccio, M.B.^{1,2} ; García, J.A.³

¹Facultad de Ciencias Veterinarias, Universidad Nacional del Centro de la Provincia de Buenos Aires (FCV-UNCPBA), Tandil, Argentina; ²Servicio de Diagnóstico Veterinario FCV-UNCPBA, Tandil, Argentina; ³Instituto de Innovación para la Producción Agropecuaria y el Desarrollo Sostenible (IPADS) Balcarce, Buenos Aires, Argentina. ✉ jorge@vet.unicen.edu.ar

Abstract

In the Buenos Aires Province, a significant number of annual cattle deaths occur for various reasons, with only a small percentage of farms conducting diagnostic confirmations. Among the primary causes of acute death, magnesium deficiency and certain infectious diseases such as bacillary hemoglobinuria and anthrax are noteworthy. Nonetheless, there are secondary factors, such as hydrallantois, which can occasionally be associated with acute death. Hydrallantois refers to the abnormal accumulation of fluid within the allantoic sac. While this condition is more commonly observed in cattle, it remains a rare occurrence in pregnancy. The initial case, which came to the attention of the Veterinary Diagnostic Service at the Faculty of Veterinary Sciences, Universidad Nacional del Centro de la Provincia de Buenos Aires (FCV-UNCPBA) in July 2018, involved a necropsy and diagnostic procedures carried out on an Aberdeen Angus cow from a herd that had witnessed four deaths within a month. The second case emerged in June 2018 when an adult Aberdeen Angus cow was identified through anamnesis and clinical examination by a private veterinarian. Unfortunately, the cow was found dead 18 days after the clinical diagnosis, prompting a post-mortem examination. During necropsy in both cases, a striking finding was the presence of severe hydrallantois in the pregnant uterus, containing more than 100 liters of allantoic fluid. Microscopically, detachment of the fetal trophoctoderm was observed with edema and mineralization, evident through an area of connective tissue within the placentomes. This report aims to outline various clinical presentations and highlight the macroscopic and microscopic observations from two cases of hydrallantois in cows. It is vital to emphasize the importance of recognizing this rare pathology as a possible differential diagnosis of acute death in cows, as a consequence of cardiorespiratory failure resulting from thoracic pressure.

Key words: Cow, acute dead, hydrallantois, placenta

Hidroalantoides en bovinos de carne: Reporte de dos casos

Resumen. En la Provincia de Buenos Aires, un número significativo de muertes anuales de ganado ocurre por diversas razones, y solo un pequeño porcentaje de establecimientos realiza confirmaciones diagnósticas. Entre las principales causas de muerte aguda se destacan la deficiencia de magnesio y determinadas enfermedades infecciosas como la hemoglobinuria bacilar y el ántrax. Sin embargo, existen causas secundarias, como el hidroalantoides, que en ocasiones pueden asociarse con muerte aguda. El hidroalantoides se refiere a la acumulación anormal de líquido dentro del saco alantoideo. Si bien esta afección se observa con mayor frecuencia en el ganado vacuno, su ocurrencia sigue siendo poco común durante la gestación. El caso inicial, que llegó a conocimiento del Servicio de Diagnóstico Veterinario de la Facultad de Ciencias Veterinarias de la Universidad Nacional del Centro de la Provincia de Buenos Aires (FCV-UNCPBA) en julio de 2018, involucró una necropsia y procedimientos diagnósticos realizados en una vaca Aberdeen Angus de un rodeo que había presenciado cuatro muertes en un mes. El segundo caso surgió en junio de 2018, cuando un veterinario privado identificó a una vaca Aberdeen Angus adulta mediante anamnesis y el examen clínico. Desafortunadamente, la vaca fue encontrada muerta 18 días después del diagnóstico clínico, lo que obligó a realizar un examen post mortem. Durante la necropsia en ambos casos, el hallazgo principal fue la presencia de hidroalantoides severo en el útero gestante, que contenía más de 100 litros de líquido alantoideo. Microscópicamente, se observó el desprendimiento del trofoectodermo fetal con edema y mineralización, evidente a través de un área de tejido conectivo dentro de los placentomas. Este informe tiene como objetivo describir varias presentaciones clínicas y resaltar las observaciones macroscópicas y microscópicas de dos casos de hidroalantoides en vacas. Es vital enfatizar la importancia de reconocer esta patología poco común como posible diagnóstico diferencial de muerte aguda en vacas, como consecuencia de una insuficiencia cardiorrespiratoria resultante de la presión torácica.

Palabras clave: vaca, muerte aguda, hidroalantoides, placenta

INTRODUCTION

Edematous conditions affecting pregnancy are uncommon during late gestation in domestic species (Momont 2005), being more frequent in cattle (Schlafer and Foster 2016). The excessive accumulation of fluid in either the amniotic or the allantoic cavities, termed respectively hydramnios and hydrallantois, are the most frequent causes of dropsy in cattle (Youngquist and Threlfall 2007), reaching over 90% of the dropsy cases. In general, both occur separately as distinct entities, but occasionally, the involvement of both compartments can be seen (Schlafer and Foster 2016). Other dropsical conditions include edema of the chorioallantoic membrane or edema within the fetus, such as fetal anasarca, fetal ascites and hydrothorax (Roberts 1986).

Normally, the origin, quantity and nature of the fluid cavity change throughout the normal gestation (Schlafer and Foster 2016). Amniotic fluid is clear and slightly viscous, and it is mostly derived from the salivary secretion of the fetus, then, its volume is largely depending on fetal swallowing. For this reason, the occurrence of hydramnios is always associated with fetal abnormalities, usually malformations (Drost 2007, Schlafer and Foster 2016). In contrast, allantoic fluid has a clear, watery consistency, and it is largely produced by excretion from the fetal kidneys (Momont 2005). Excessive accumulation of allantoic fluid is attributed to placental pathology, and it is much more frequent than hydramnios (Wintour et al. 1986, Drost 2007). Among the various hydropic conditions that can affect a pregnant cow, this is the sole condition that qualifies as a genuine emergency with favorable response when treated (Momont 2005).

Hydrallantois is associated with a decrease in the number of caruncles, and although the origin of this reduction remains undetermined (Youngquist and Threlfall 2007), transplacental poisoning and fetal damage leading to hydrallantois associated with the ingestion of *Sida Carpinifolia* in cattle has been described (Reis et al. 2019). It is frequently associated with non-functional caruncles in one of the uterine horns, and enlargement of the remaining placentomes (Drost 2007, Schlafer and Foster 2016). The remaining caruncles tend to show hypertrophy. The fetal membranes are usually only slightly thickened, although this is not always the case (Schlafer and Foster 2016).

The aim of this paper is to describe two cases of hydrallantois in beef cattle from the province of Buenos Aires, Argentina, including the associated gross and microscopic findings. This work also aims to appoint the importance of reaching a diagnosis in cases of acute and subacute death in cattle.

MATERIALS AND METHODS

The first case (Case 1) took place on a beef cattle farm located near Azul, province of Buenos Aires. The herd consisted of 250 Aberdeen Angus, cows that came from Santa Fe province five months earlier (May, 2018). The animals were grazing on natural pasture. The sanitary plan included vaccination against *Clostridium chauvoei*, *Cl. septicum*, *Cl. perfringens* types C and D, and

Escherichia coli, parenteral administration of copper and oral supplementation with mineral salt blocks, including magnesium. Calving had started during the month of July, and upon consultation four animals had been found dead during the past month. In July a necropsy was performed on an adult Aberdeen Angus cow with approximately 12-15 hours postmortem. Autopsy was performed and samples of liver, heart, lungs, spleen, kidneys, uterus, and placenta were collected for histopathological analysis.

The second case (Case 2) took place on a beef cattle farm located in Saladillo, province of Buenos Aires. The herd consisted of 151 red Aberdeen Angus cows. The animals were grazing on natural pasture and the sanitary plan included a double pre-breeding dose of vaccine against reproductive diseases (Bovine herpesvirus type 1, Bovine viral diarrhea virus, *Campylobacter fetus*, *Histophilus somni* and *Leptospira interrogans*). The cows had been inseminated in October 2017, and calving had started during mid-June 2018. The problem started with a cow exhibiting bilateral abdominal distention beginning at the eight months of gestation. An excessive amount of fluid was noted on rectal examination, preventing palpation of fetal structures. Fifteen days later, the animal was found lying in ventral recumbency and unable to stand. The cow died three days afterwards, and a necropsy was performed. Necropsy was performed and samples from placenta, including placentomes and interplacentomal area, were collected for histopathological analysis.

The samples for histopathological analysis from both Case 1 and Case 2 were fixed in 10% neutral buffered formalin (pH 7.2) for 48h. Samples were then dehydrated with ethanol and embedded in paraffin to obtain blocks which were then sectioned by means of a rotary microtome to 6- μ m-thickness sections. They were then rehydrated in distilled water and stained with hematoxylin and eosin (H&E).

RESULTS

The animal from case 1 had been found dead, lying in sternal recumbency with its hindlimbs extended caudally, interpreted as an acute death (Figure 1).



Figure 1. Case 1, Aberdeen Angus, pregnant cow. The animal was found lying in sternal recumbency with its hindlimbs extended, indicating a sudden death.

On external examination, the abdomen was markedly bilaterally distended. At necropsy, when the abdomen of the cow was opened, the abdominal musculature was separated by large quantities of a yellow, viscous material compatible with edema and both uterine horns were observed to be distended to more than 15 times their normal size. The incision of the right (non-pregnant) horn resulted in the exit of about 50 to 70 liters of allantoic fluid (Figure 2). The left horn also exhibited a large volume of allantoic fluid. The uterus was gravid with a full-term fetus and did not show any gross abnormalities.

The cotyledons had a thickness of 2 to 3 cm. The placentomes were pedunculated and measured 7 cm in diameter, and 2.5 to 3 cm deep. No other macroscopic lesions were observed.



Figure 2. Case 1, Aberdeen Angus, pregnant cow. Note the abundant amount of allantoic fluid coming out from the right uterine horn.

In Case 2, grossly the left uterine (pregnant) horn was distended to more than 10 times its normal size (Figure 3). After incision, about 80 liters of clear watery fluid came out

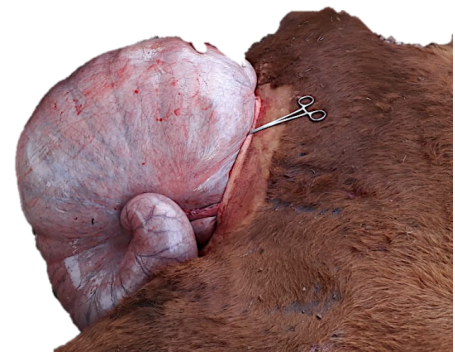


Figure 3. Case 2, Aberdeen Angus, pregnant cow. Marked distension of left uterine horn with abundant allantoic fluid.

In both cases, the microscopic lesions observed in the placenta were similar and included separation of the fetal trophoblast by evident regions of connective tissue within the placentomes, and edematous caruncular stroma (Figure 4 A). Extensive foci of mineralization, occasionally associated with the absence of chorionic villi and uterine epithelium, disorganized villi with low or absence of vascularization (immature chorionic villi), and mild diffuse

congestion of both the maternal and fetal endothelium were also present (Figure 4 B). Only in Case 1 samples other than placenta were collected, observing marked diffuse cytoplasmic vacuolation in hepatocytes, indicative of hydropic degeneration, along with the loss of hepatocyte cords. The remaining organs, i.e., the heart, lungs, kidneys and spleen, did not exhibit any relevant microscopic lesions.

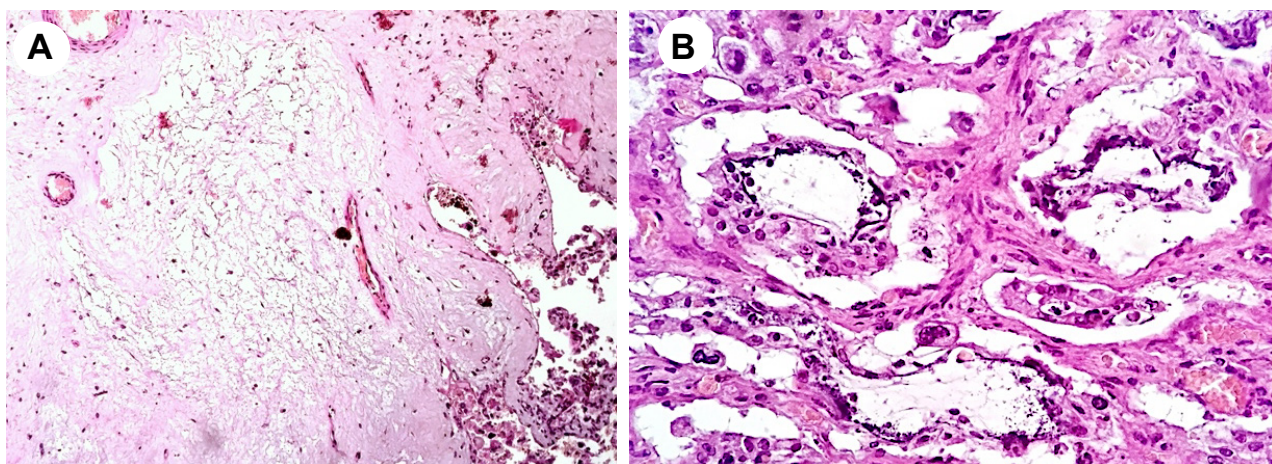


Figure 4. Cow, Aberdeen Angus, placenta. A) Caruncular stroma with marked edema, B) Placenta with multiple mineralization of fetal trophoblast and absence of chorionic villi and uterine epithelium. Note minimum villi vascularization.

DISCUSSION

Hydrallantois has been described in both dairy and beef cows. Typically, allantoic fluid volume increases steadily from late gestation to roughly 10 L, ranging between 8 and 15 L (Drost 2007). In cases of hydrallantois, this increase is usually rapid, progressing over 5 to 20 days (Pickles 1987). The fluid composition closely resembles plasma, with markedly higher sodium, potassium, chloride and creatinine levels than normal allantoic fluid (Youngquist and Threlfall 2007). According to the situation Momont (2005) described for hydrallantois, the cases reported in this work exhibited large amounts of allantoic fluid, nearing roughly 150 L. Although only acute death was observed in Case 1, Case 2 exhibited a subacute course allowing for clinical signs to be observed. Sudden death of Case 1, we believe occurred by compression of thoracic cavity causing asphyxiation, and impediment of normal systemic circulation, as occurs in bloat (Yirdachew and Mekonnen 2022).

The presence of multiple fetuses, in vitro fertilization, and transgenic and cloning technologies have been associated with an increased risk of developing this condition (Youngquist and Threlfall 2007, Schlafer and Foster 2016), although these findings were not observed in the cases described here. Bovine viral diarrhoea virus has also been implicated in cattle hydrallantois cases (Collyer 1990). Placental abnormalities found in the presence of hydrallantois, such as reduced vascularization, particularly at the apex of the villi and loss of differentiation of the trophoblastic epithelium (primitive villi), suggesting that an insufficient development of villi could contribute to the physiopathology of this condition (Loi et al. 2006, Feliciano et al. 2013).

Hydrallantois is associated to diseased uterus in which most caruncles in one horn are not functional with consequent reduction of placental vascularization resulting in metabolic changes thereby accumulating fetal fluid (Drost 2007, Kapadiya et al. 2018). The 2 cases presented herein had low number of placentomes with increased size, low vascularization and inadequate development (immature villi), which is a compensatory mechanism during gestation, of congenital origin with inadequate uterine development, as no inflammatory findings were present. Consequently, edema formation due to low vascularization leads to further hypoxia causing an increase in vessel permeability and interstitial fluid accumulation, leading to insufficient transplacental exchange rate and accumulation of fluid in the allantoic cavity (Dini et al. 2020). It has also been associated with a recessive fetal abnormality manifested with fetal polyuria and subsequent hydrallantois (Sasaki et al. 2016). Even though no genetic and hereditary factors were evaluated in the cases described here, the fetus from both cases did not exhibit gross renal abnormalities. Findings such as at-term fetuses exhibiting ascites and an enlarged umbilical cord are frequent findings associated to placental dysfunction, including hydrallantois (Constant et al. 2006, Schlafer and Foster 2016). Although no fetal abnormalities were observed grossly in Case 1, the fetus from Case 2 did exhibit both ascites and an enlargement of the umbilical cord. Although the cause of the edema within the placentomes is unknown, we believe it could be directly

associated with hydrallantois, as fetal membranes play an important role in regulating the composition and volume of fetal fluids (Wintour et al. 1986).

Gross and microscopic findings in cases of hydrallantois include an inadequate number of caruncles and adventitial placentation. The remaining caruncles tend to be hyperthrophied, and fetal membranes are usually slightly thickened (Schlafer and Foster 2016). In both cases, placentomes were slightly enlarged compared to previous reports on normal placentae. Normal size during late gestation is 5 to 8 cm diameter (Laven and Peters 2001, Barbeito 2010, Kouamo et al. 2018), 2 to 3 cm width (Schlafer et al. 2000) and 3 cm depth (Ribeiro et al. 2008), and an individual weight between 51 and 114 g (Laven and Peters 2001, Constant et al. 2006, Adeyinka 2012). Some works report placentomes with a diameter of 12 cm (MacDonald 2011). Despite the severity of the inflammatory lesions and mineralization in Case 2, these findings have been described in normal placentae and can thus be considered incidental (Schlafer and Foster 2016). Hydropic degeneration of hepatocytes found in Case 1 may be produced by anorexia due to prolonged discomfort or recumbency.

The diagnosis of hydrallantois in cattle can be made by rectal palpation of a distorted uterine horn without palpation and ballottement of the fetus and the placentomes (Bhattacharyya et al. 2012). However, as seen in Case 1, the course may be too acute to enable the diagnosis employing rectal palpation. A rapid bilateral abdominal distention history in the last 15 to 20 days suggests hydrallantois. If a C-section is performed, confirmation is made by observing large quantities of clear allantoic fluid (Bhattacharyya et al. 2012). In both of the cases presented here, a diagnosis of hydrallantois was made post-mortem based on the origin of the fluid within the uterus, the presence of at-term fetuses lacking gross and microscopic abnormalities (although one of them exhibited ascites), and the presence of edema within the intercotyledonary region and the placentomes. We hypothesized that the underlying factor leading to the demise of Case 1 was acute cardiorespiratory failure resulting from heightened intraabdominal pressure from the enlarged uterus. It is unlikely that this condition was the cause of death of the animals that had died previously in the herd, but no necropsies were performed in those cases. In Case 2, only one animal developed hydrallantois, and though treatment is favorable for these cases, diagnosis was not proper when still alive, not reaching for treatment. The most common treatment for hydrallantois is termination of pregnancy by means of cloprostenol or other prostaglandin F_{2α} analogs. Induction with corticosteroids and estrogen preparations has also been reported (Sharp et al. 1978). However, delivery by C-section is the preferred choice when the animal may not withstand the stress of natural parturition (Bhattacharyya et al. 2012). Particularly, early hydrallantois detection is essential as applying treatment with favourable results.

CONCLUSION


In Argentina, several acute deaths among adult cattle occur without reaching a definitive diagnosis or simply because of a lack of diagnosis, with no official data

available and numerous cases remaining undiagnosed. Because of this, we encourage performing a full diagnosis work-out in all acute or sub-acute death cases to find other common or uncommon conditions that could affect herds of beef cows. Though unusual, hydrallantois should be considered a differential diagnosis for acute death in beef cows, including hypomagnesaemia, anthrax, bacillary hemoglobinuria, nitrate intoxication and plant poisoning.

Acknowledgements. The authors would like to thank Vet. Marcelo Debandi for submitting the samples of one of the cases reported in this manuscript.

ORCID

García, J. P.  <https://orcid.org/0000-0003-4694-6996>

Riccio, M.B.  <https://orcid.org/0000-0002-8449-4823>

García, J.A.  <https://orcid.org/0000-0002-8047-6724>

REFERENCES

- Adeyinka FD. The development of the bovine placenta and associated structures during gestation. Massey University. 2012.
- Barbeito CG. Patología placentaria: conocimientos generados por estudios experimentales. In *A.N.A.V.* 2010; 87-116.
- Bhattacharyya HK, Hussain Dar S, Fazili M-U-R, Hafiz A. A typical case of hydrallantois accompanied by fetal monstrosity in a local ewe of Kashmir. *Vet. Res. Forum: Int. Q. J.* 2012; 3(3): 221-223.
- Collyer JH. Hydrallantois in cows. *The Vet. Rec.* 1990; 127(2): 47.
- Constant F, Guillomot M, Heyman Y, Vignon X, Laigre P, Servely JL, Renalt JP, Chavatte-Palmer P. Large Offspring or Large Placenta Syndrome Morphometric Analysis of Late Gestation Bovine Placentomes from Somatic Nuclear Transfer Pregnancies Complicated by Hydrallantois. *Biol. of Reprod.* 2006; 75(1): 122-130.
- Dini P, Carossino M, Loynachan AT, El-Sheikh Ali H, Wolfsdorf KE, Scoggin KE, Daels P, Ball BA. Equine hydrallantois is associated with impaired angiogenesis in the placenta. *Placenta.* 2020; 93:101-112.
- Drost M. Complications during gestation in the cow. *Theriogenol.* 2007; 68(3): 487-491.
- Feliciano MAR, Cardilli DJ, Crivelaro RM, Garrido E, Silva MAM, Castanheira TLL, Vicente WRR. Hydrallantois in a female dog: a case report. *Arq. Bras. de Med. Vet. e Zootec.* 2013; 65(4): 1091-1095.
- Kapadiya PS, Parikh SS, Chauhan PM, Sutaria TV, Nakhasi HC. Management of hydroallantois in a Jaffrabadi buffalo: A case report. *J. pharmacogn. Phytochem.* 2018; SP1: 1534-1536
- Kouamo J, Saague AMN, Zoli AP. Determination of age and weight of bovine fetus (*Bos indicus*) by biometry. *J. Livestock Sci.* 2018; 9: 9-15.
- Laven R, Peters A. Gross Morphometry of the Bovine Placentome during Gestation. *Reprod. Dom. Anim.* 2001; 36(6): 289-296.
- Loi P, Clinton M, Vackova I, Fulka J, Feil R, Palmieri C, Della Salda L, Ptak G. Placental abnormalities associated with post-natal mortality in sheep somatic cell clones. *Theriogenol.* 2006; 65(6): 1110-1121.
- MacDonald R. Hydrops in a heifer as a result of in-vitro fertilization. *Can. Vet. J.* 2011; 52(7): 791-793. <http://www.ncbi.nlm.nih.gov/pubmed/22210947>
- Momont H. Bovine Reproductive Emergencies. *Vet. Clin. North Am.: Food Anim. Pract.* 2005; 21(3), 711-727.
- Pickles AC. Current therapy in theriogenology, 2nd edn, edited by David A. Morrow, published by W. B. Saunders Co, Philadelphia. *Equine Vet. J.* 1987; 19(3): 217-217.
- Reis MO, Raquel AS, Cruz Luiz GS, Oliveira Daniele M, Bassuino Claiton I, Schwertz Matheus V, Bianchi LS, Saulo P, Pavarini DD. Hydrallantois in cows naturally poisoned by *Sida carpinifolia* in Brazil. *J. Vet. Diagn. Invest.* 2019; 31(4): 581-584
- Ribeiro AA, de Oliveira Lacerda PM, Pereira de Melo M, de Carvalho Balieiro JC, de Souza RR. Placental microstructure and efficiency in cloned bovines: a design-based stereological approach. *Cell Tissue Res.* 2008; 333(1):105-14.
- Roberts SJ. Diseases and accidents of the gestation period. In *Vet. Obstet. Genit. Dis., Theriogenol.*, 3rd ed., Woodstock Vermont. 1986; p. 213-217.
- Sasaki S, Hasegawa K, Higashi T, Suzuki Y, Sugano S, Yasuda Y, Sugimoto Y. A missense mutation in solute carrier family 12, member 1 (SLC12A1) causes hydrallantois in Japanese Black cattle. *BMC Genomics.* 2016; 17(1): 724.
- Schlafer DH, Fisher PJ, Davies CJ. The bovine placenta before and after birth: placental development and function in health and disease. *Anim. Reprod. Sci.* 2000; 60-61: 145-160.
- Schlafer DH, Foster RA. Female Genital System. In *Jubb, Kennedy & Palmer's Pathol. Domest. Anim.:* 2016; 3: 358-464.
- Sharp AJ, Bierschwal CJ, Elmore RG, Youngquist RS, Jenkins AL, Kesler DJ, Garverick HA. A case report response of two cows with hydramnios and hydrallantois to treatment with cloprostenol (ICI 80, 996). *Theriogenol.* 1978; 10(1): 27-33.
- Wintour EM, Laurence BM, Lingwood BE. Anatomy, physiology and pathology of the amniotic and allantoic compartments in the sheep and cow. *Aust. Vet. J.* 1986; 63(7): 216-221.
- Yirdachew T, Mekonnen G. Review on Bloat in Cattle. *J. Vet. Med. Animal Sci.* 2022; 5(1): 1101.
- Youngquist RS, Threlfall WR. *Curr. Ther. Large Anim. Theriogenol.*, 2nd ed. St. Louis: Saunders-Elsevier. 2007.

Citación recomendada

García JP, Riccio MB, García JA. Hydrallantois in beef cattle: Two case reports. *Rev. Vet.* 2023; 34(2): 96-100. doi: [hftp://dx.doi.org/](https://dx.doi.org/)